

Nasal Tip Overprojection

Algorithm of Surgical Deprojection Techniques and Introduction of Medial Crural Overlay

Peyman Soliemanzadeh, MD; Russell W. H. Kridel, MD

Objectives: To discuss the evaluation of the overprojected nasal tip, present an algorithm of various treatments for deprojection of the nasal tip, and introduce our experience of greater than 10 years with medial crural overlay.

Design: Retrospective review of a large sequential series of patients undergoing rhinoplasty who were treated with various deprojection techniques by the senior author (R.W.H.K.) from January 1, 1991, through December 31, 2002. Patients underwent preoperative and postoperative evaluation during this period on a regular basis to record the effects of various approaches on nasal projection, rotation, need for revision, and patient satisfaction. Medical records and photographic documentation were reviewed. The occurrence of postoperative complications and secondary revision procedures were noted. We used the information obtained to evaluate and expound on an algorithmic paradigm for treatment of nasal tip overprojection.

Results: From 1991 to 2002, 130 cases used 1 or more of the senior author's preferred methods for deprojec-

tion. Ten patients were excluded owing to the primarily reconstructive nature of their surgery. Of the remaining 120 patients, 3 (2.5%) underwent minor revision of dorsal irregularities and another 5 (4.2%) underwent tip revision. Only 9 patients (7.5%) required concomitant alar base reduction. One patient had postoperative epistaxis, and there were no cases of postoperative functional complaints.

Conclusions: Deprojection of the overprojected nasal tip can be accomplished successfully with a handful of properly used techniques. Once proper analysis has been accomplished, an algorithm can be used to help simplify the approach to deprojection. These techniques offer sound functional approaches to effect deprojection while controlling the level of rotation. The beneficial effects observed using this algorithm are attested to by the minimal number of complications, the relatively low number of patients requiring revision, and the overall long-term patient satisfaction with their results.

Arch Facial Plast Surg. 2005;7:374-380

NASAL TIP PROJECTION HAS been defined as the distance along a perpendicular line from the vertical facial plane to the most anterior projecting point of the nasal tip. When the nose is overprojected, it draws undue attention and the normal nasofacial harmony is disturbed. This overprojection can vary from a subtlety noticed only on close analysis to a grossly overprojected "Pinocchio" nose.

Numerous reports have not only defined the proportions and angles that constitute the aesthetic ideal but also developed formulas to determine how closely an individual patient matches these aesthetic ideals. The thoughtful analysis by Crumley and Lanser¹ is perhaps the most accepted and quoted (**Figure 1**). However,

the variables suggested by Crumley and Lanser¹ and many of those who have followed do not take into consideration that projection of the nasal tip cannot be viewed in isolation and that the height of the nasal radix must be factored into the equation lest a nose be judged as overprojected when the only problem is a low radix.¹⁻³ In addition, few reports outline a systematic approach on the choice of techniques to accomplish the deprojection once this analysis has been completed.

It has been our experience that true nasal tip overprojection is uncommon. More often, it is relative and multifactorial. In the past, attention in the literature has largely been directed toward achieving and maintaining increased projection. As such, the overprojected nasal tip, as the focus of far less attention, continues to represent a chal-

Author Affiliations: Division of Facial Plastic Surgery, Department of Otolaryngology-Head and Neck Surgery, The University of Texas Health Science Center, Houston.

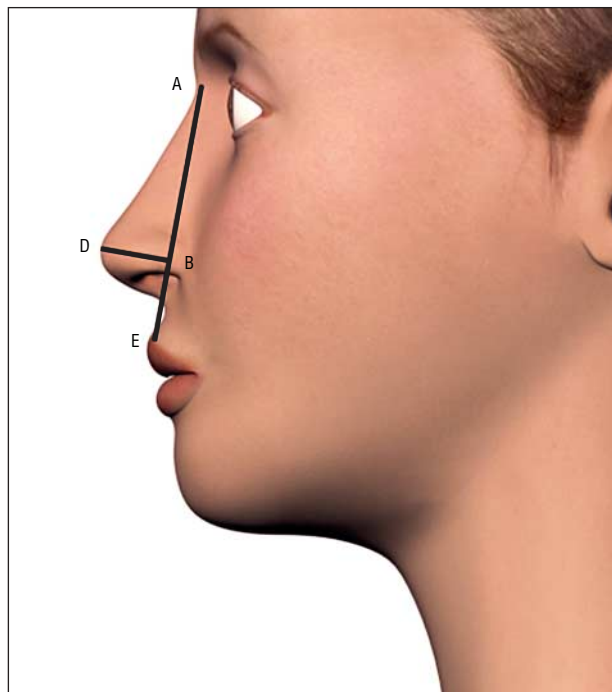


Figure 1. Computer-generated image depicts ideal nasal projection as derived by analysis by Crumley and Lanser.¹ Their results defined an ideal ratio equal to 0.2833 using the length from nasion to upper vermilion–cutaneous junction of the upper lip (AE) compared with the length of a perpendicular from this line to the tip-defining point (BD).

lenging task for even the most experienced facial plastic surgeon. To help simplify the surgical approach to the overprojected nasal tip, we completed a retrospective analysis of the patients who underwent deprojection procedures in the private practice of the senior author (R.W.H.K.). We used this review to refine our algorithm of preferred methods in achieving deprojection and introduce our experience with medial crural overlay (MCO).

METHODS

We completed a retrospective review of sequential patients presenting to the senior author's private practice for rhinoplasty and undergoing various methods of deprojection from January 1, 1991, through December 31, 2002. Deprojection procedures used included full-transfixion incision, release of tension septum, lateral crural overlay (LCO), dome truncation, MCO, and combinations of them. The surgical techniques and our review of our experience with LCO and dome truncation have previously been detailed in isolation.⁴⁻⁶ However, an overview of these techniques and a complete description of our technique for MCO are described herein.

Although this report is retrospective, patient management was prospectively performed using an algorithm based on early results among patients treated by the senior author (R.W.H.K.) in the late 1980s. Medical charts reviewed had been logged into our data bank postoperatively according to the surgical procedure code and diagnosis of overprojection after direct analysis at the time of surgery. Detailed operative schematics filled out at the time of surgery helped ensure the accuracy of our data analysis. Those patients who had undergone a deprojection procedure or who had been diagnosed as having overprojection were included in the medical chart review. Patients' medical records, including preoperative and postoperative photo-

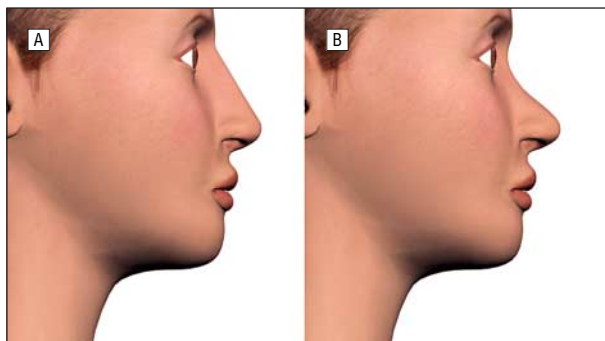


Figure 2. Computer-generated image demonstrates the importance of the radix in aesthetic analysis. The height and position of the radix affect each other, define the nasofacial angle, and serve as the counterpoise of the nasal base. Although projection is the same in parts A and B, the change in radix positioning causes the illusion of overprojection in part B.

graphs, were independently reviewed by the other author (P.S.) for facial analysis and the need for and achievement of deprojection. We excluded those patients judged to have undergone LCO or truncation for reasons other than deprojection on the basis of notes or a review of photographs.

Patients underwent preoperative and postoperative evaluation during this period on a regular basis to record the effects of various approaches on nasal projection, rotation, need for revision, and patient satisfaction. We reviewed major and minor secondary revision procedures that patients underwent, postoperative complications, and any functional complaints.

FACIAL ANALYSIS

When discussing facial aesthetics, it is wise to understand that formulas are only guidelines to be tempered by changing aesthetics, patient desires, and existent anatomy. Once the patient's objectives are understood, the surgeon can develop a goal based on his or her experience and analysis of the anatomy of the nasal and facial profile.

First, one must understand the critical importance of examining nasal tip projection in relation to the height of the radix. Sheen and Sheen⁷ long ago recognized that in evaluating nasal projection, the radix should not be considered a separate unit but a "key part of a dynamic form" (**Figure 2**). The tip is only projected in relation to the projection of dorsal height at the nasion. More recently, Byrd and Hobar² and McKinney and Sweiss³ have also discussed the importance of the radix height. As such, one needs to consider not only the height and position of the radix but also the nasofacial angle produced in its relation to the nasal tip. One must subsequently ensure that other complicating dynamics that give the illusion of overprojection are not in place. In addition to a low radix, a tension septum, saddle-nose deformity, retrognathia, and short upper lip also give the illusion of overprojection and must be excluded.

When true overprojection is determined, the surgeon can then perform an objective analysis. Components of the nasal anatomy that lead to tip overprojection can include (1) overelongated alar cartilages, including lateral crura, medial crura, angle of divergence (intermediate crura), or a combination; (2) a tension nose with overdeveloped quadrangular cartilage; (3) a combination of these components; and (4) trauma or iatrogenic injury.

Having completed analysis of nasal projection, the next step is to determine whether rotation is adequate or will need to be addressed, as many deprojection techniques can or will alter rotation. The nose is further examined for tip asymmetries, tip shape, size and contour, skin thickness, dorsal humps and irregularities, nasal valve competence, and other functional components. With the analysis complete, the surgeon proceeds to

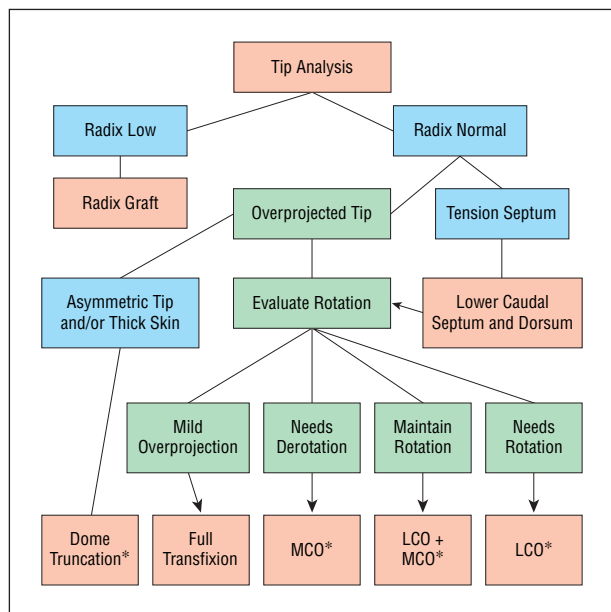


Figure 3. Algorithm developed to help simplify the approach to deprojection. Analysis begins with evaluation of the radix. Asterisk indicates that full-transfixion incision can be added to these procedures to allow further retrodisplacement. MCO indicates medial crural overlay; LCO, lateral crural overlay.

the algorithm to determine how to best achieve nasal deprojection while controlling the extent of rotation.

ALGORITHM

To bring new focus on the radix, our algorithm for the overprojected nose begins with evaluation of the radix (**Figure 3**). Often what is needed to bring the nasal tip back into proper balance with the remainder of the patient's profile is a radix graft rather than deprojection. For that reason, we stress the importance of the radix by placing it at the top of the evaluation. In these cases, overprojection is not the problem, and a simple radix graft will restore balance.

Once the radix has been evaluated and the nose has been defined as truly overprojected, attention can then be turned to the next step. If minimal deprojection is needed, the surgeon can make a simple full-transfixion incision to effect the desired retrodisplacement. However, when more pronounced deprojection is necessary, the surgeon must evaluate rotation.

In the classic nasal tripod theory, a standard way to effect retrodisplacement of the tip is to shorten one or both of the legs of the tripod (**Figure 4**). However, if one shortens only one of the legs, a change in rotation will ensue. One can take advantage of this principle to accomplish retrodisplacement and a change in rotation by selecting the proper technique. Kridel and Konior⁴ showed that when overprojection is accompanied by tip ptosis, LCO (which shortens the lower lateral crural leg) permits incremental retrodisplacement with increased rotation. On the other hand, MCO, which shortens the medial crural leg of the tripod, leads to controlled deprojection and decreased rotation. When used together at the same surgical intervention (to shorten both tripod legs), MCO and LCO can effect large amounts of retrodisplacement with little effect on rotation. These 2 techniques, alone or in combination, accomplish the needed retrodisplacement in most patients. It is relatively uncommon to need further deprojection than can be accomplished with MCO or LCO alone. Large increments of retrodisplacement can be achieved with these techniques, and therefore the surgeon needs to consider that the skin-soft tis-

sue envelope must be able to contract down to the newly deprojected cartilaginous support structure or one will risk losing refinement in tip definition.

In those patients with a tension nose deformity, we recommend that attention first be directed to lowering the overdeveloped cartilaginous dorsum, which often tents up the tip artificially. Thereafter the surgeon can follow the same algorithm for deprojection. In our experience, most of these patients require increased rotation and experience excellent results when treated with LCO.

In the rare situations when further deprojection is required than can be accomplished with LCO or MCO, the surgeon can choose 1 of 2 separate options. To effect retrodisplacement while maintaining rotation, MCO can be combined with LCO. On the other hand, as indicated in the last arm of our algorithm, it has been our experience that when significant tip asymmetry is present or when the patient has thick skin, dome truncation can be used to accomplish much of the same deprojection in a slightly easier 1-step maneuver. Finally, any one of the procedures can be combined with a full-transfixion incision to cause another incremental decrease in projection.

SURGICAL TECHNIQUE

Bilateral alar marginal incisions and an inverted V-shaped mid-columellar incision are made. The nasal skin is elevated from the alar cartilages in the supraperichondrial avascular plane up to the radix. Wide undermining is necessary to allow a favorable redraping advantage for the lengthy skin-soft tissue envelope that characterizes the overprojected nose. Dorsal profile adjustments, if needed, precede tip work finalization to minimize disruption of the reconstructed nasal tip.

Cephalic trim of the lower lateral cartilages, leaving at least a 6-mm-wide strip (depending on the intrinsic cartilaginous strength), is then performed to promote tip refinement. The level of deprojection necessary is then reevaluated. When increased rotation is desired, LCO is performed (**Figure 5**). The nasal tip is repositioned to an aesthetically pleasing position. The incisions in the repositioned lateral crura are then planned so as to cross the central-lateral portion of each lateral crus. The cartilage cut extends in a straight line from the cephalic to the caudal crural margin, with care taken to stay at least 1 cm away from the dome. Before making the cartilage cut, the vestibular skin is elevated from the overlying lateral crus for approximately 5 mm on each side of the planned rotation point. Release of the vestibular skin also releases tethering forces that could restrict tip rotation, and it allows for safe transcartilaginous suture placement. In patients who have overprojection and downward displacement of the tip, the free anterior segment of the lateral crus is rotated and undergoes retrodisplacement over the stationary, posteriorly based lateral crural flap. With the overlay, superior rotation of the tip functionally shortens the lateral crura. The integrity of the divided lateral crus is then reestablished with 6-0 permanent transcartilaginous, horizontal mattress sutures. One can judge the resultant rotation and make adjustments in the amount of overlay and placement of the sutures as needed. After tip rotation, the inferior corner of the lateral crural transection margin may extend below the existing caudal alar cartilage margin and may be excised with a blade to create a smooth inferior alar cartilage border.

On the other hand, if the nose is overrotated or if the reason for increased projection is secondary to overelongated medial crura, the decision is made to proceed with MCO (**Figure 6**). Incisions cross the central portion of each medial crus. Unlike other Lipsett-like transection techniques, MCO requires no cartilage to be excised. As such, there is no need to

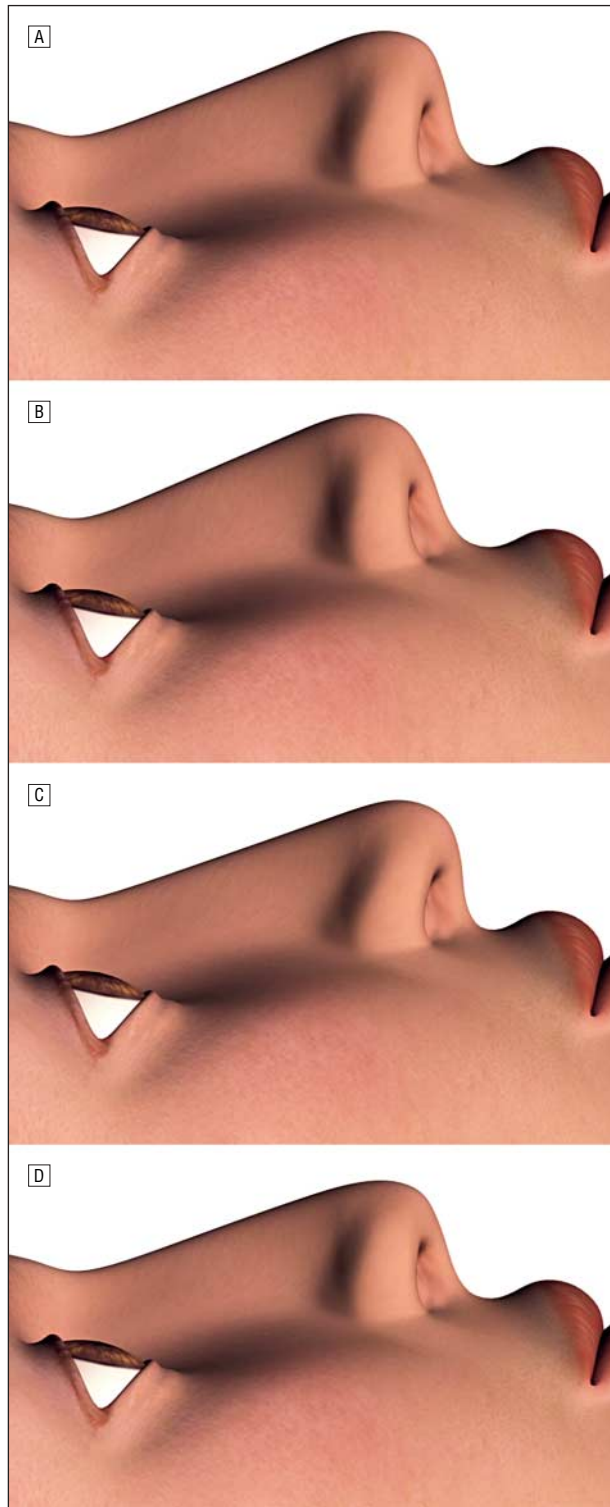


Figure 4. Computer-generated images demonstrate the Anderson tripod theory. Analysis of the nose must allow for the subtleties. If part A is a normal nose, shortening of the lateral crura (B) results in an increase in rotation and subtle deprojection. Shortening of the medial crura (C) results in a decreased nasolabial angle and retrodisplacement. Finally, if the medial and lateral crura are shortened equally (D), there is a resultant retrodisplacement without change in rotation.

predetermine which portion of the medial crus needs to be removed. As with LCO, before making the cartilage cut, the vestibular skin is elevated from the overlying medial crus, thereby

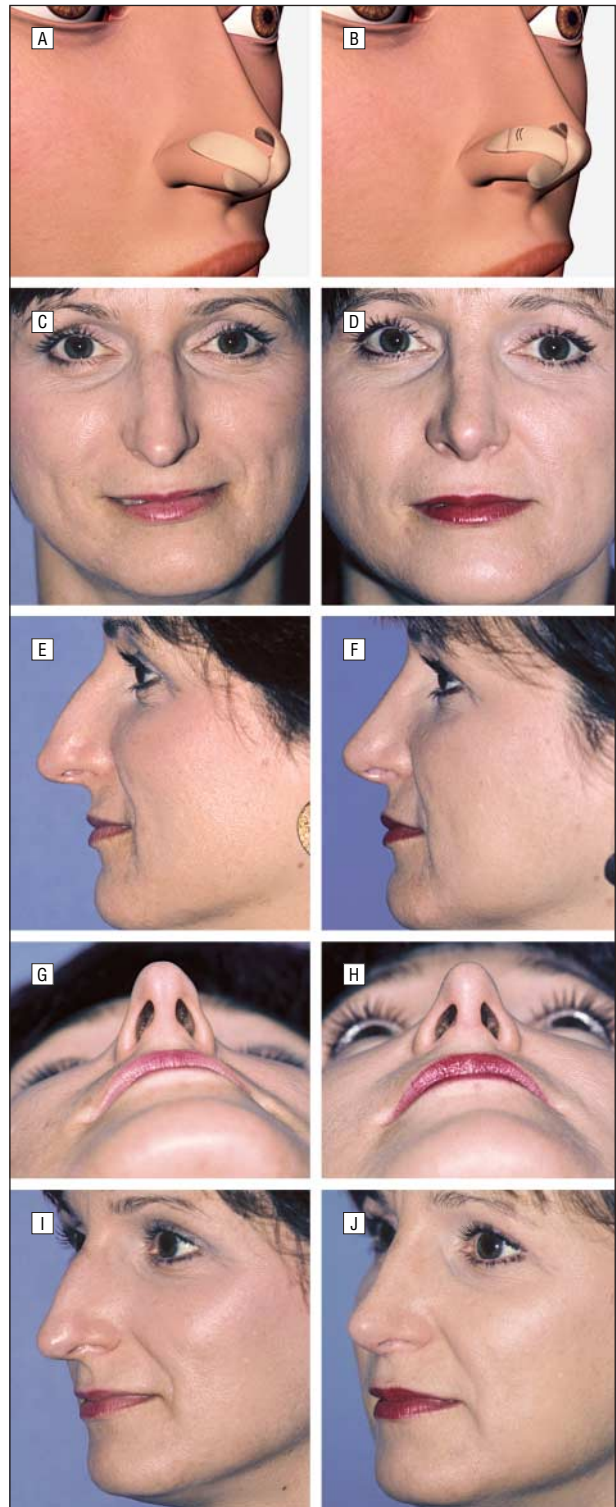


Figure 5. Lateral crural overlay (LCO) allows for controlled retrodisplacement along with increased rotation. Computer-generated images (A and B) illustrate a representative result of LCO. Preoperative and 18-month postoperative photographs show the frontal (C and D, respectively), profile (E and F, respectively), base (G and H, respectively), and three-quarter (I and J, respectively) views of a patient who underwent LCO, cephalic trim, full-transfixion incision, and double-dome suture.

permitting safe transcartilaginous permanent suture placement. After rechecking the ideal tip projection, the integrity of the medial crus is reestablished by overlapping and stabi-

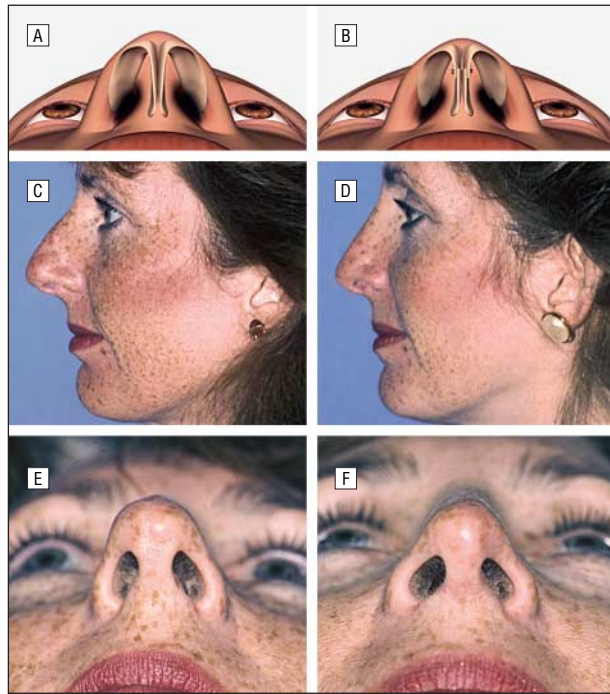


Figure 6. Medial crural overlay (MCO) allows for controlled retrodisplacement with a decreased nasolabial angle. Computer-generated images (A and B) illustrate a representative result of MCO. Preoperative and 1-year postoperative photographs show the profile (C and D, respectively) and base (E and F, respectively) views of a patient who underwent MCO, cephalic trim, and double-dome suture.

lizing the cartilage with 6-0 permanent transcartilaginous, horizontal mattress sutures. The 2-point fixation obtained with this suturing technique gives excellent long-term stability while allowing deprojection of the nasal tip into proper position. Moreover, the overlapping of the medial crural segments adds structural strength to the medial crura.

When more deprojection is required than can be effected by LCO or MCO, a combination of both techniques can be used to effect retrodisplacement of the nasal tip without significant changes in tip rotation (**Figure 7**). In these cases, LCO precedes MCO. This order allows for control over the extent of deprojection and allows the surgeon to exactly determine what, if any, changes are desired in tip rotation.

In those patients who have overprojection and preexisting tip asymmetries or overly thick skin, the surgeon may decide to proceed with dome truncation, as described by Kridel and Konior⁵ (**Figure 8**). With dome truncation, after conservative cephalic trim is completed, the vestibular skin underlying the angle of the domes is elevated for approximately 1 cm. Blunt forceps are then introduced between the vestibular skin and the dome cartilages. The alar cartilages are then elevated behind the existing domes to delineate the precise location of the tip-defining point. With the alar cartilages tented up, the overprojected distance is subtracted from the most forward projecting point of the domes and marked. The measurement is critical as it marks the new tip-defining point, which in turn will define the ultimate tip projection.

A 6-0 permanent mattress suture is placed across the dome through the lateral and medial crura, with care taken to bury the suture within the vestibular pockets. This suture is placed immediately posterior to the desired defining point of the tip and must be oriented parallel to the intended dome plane of dome truncation. By placing this suture just below the proposed truncation, the relationship between the lower lateral and medial crura is maintained so that rotation will remain un-

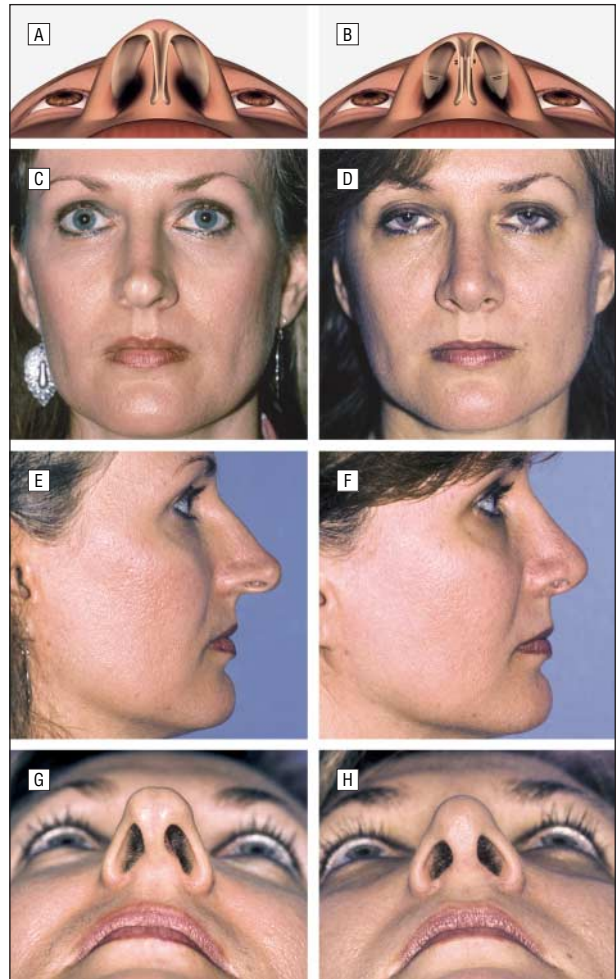

Figure 7. Lateral (LCO) overlay and medial crural overlay (MCO) can be combined when more significant deprojection is needed. Computer-generated images (A and B) illustrate a representative result after LCO and MCO are combined. Preoperative and 1-year postoperative photographs show frontal (C and D, respectively), profile (E and F, respectively), and base (G and H, respectively) views of a patient who underwent LCO, MCO, full-transfixion incision, and cephalic trim.

changed. The overprojected alar domes are then excised by transecting the lobular cartilages along the previously marked projection line, just anterior to the stabilizing sutures. This cut should be oriented just above and slightly oblique to the dorsal profile line, so that the inferior margin of the recreated crural junction lies slightly anterior to the cephalad margin. This arrangement achieves maximal lobular refinement and produces a supratip break along the new profile line. A stable and well-tailored lobular cartilage complex minimizes the chance for notching, valve collapse, or tip asymmetry. As with the combination of LCO and MCO, where the medial and lateral crura are shortened by overlay, nasal rotation remains unchanged (as predicted by the tripod theory) while achieving deprojection because dome truncation allows for equivalent amounts of the medial and lateral crura to be excised.

The nasal skin is then redraped, and the tip is reevaluated for position and definition. If greater tip refinement is desired, a 6-0 permanent suture is placed in a double-dome fashion. If any concerns exist regarding loss of tip support after completion of the alar alterations described herein, the medial crura should be reapproximated with buried 6-0 permanent mattress sutures. Should even further deprojection be needed, the hemitransfixion incision is converted to a full transfixion. The

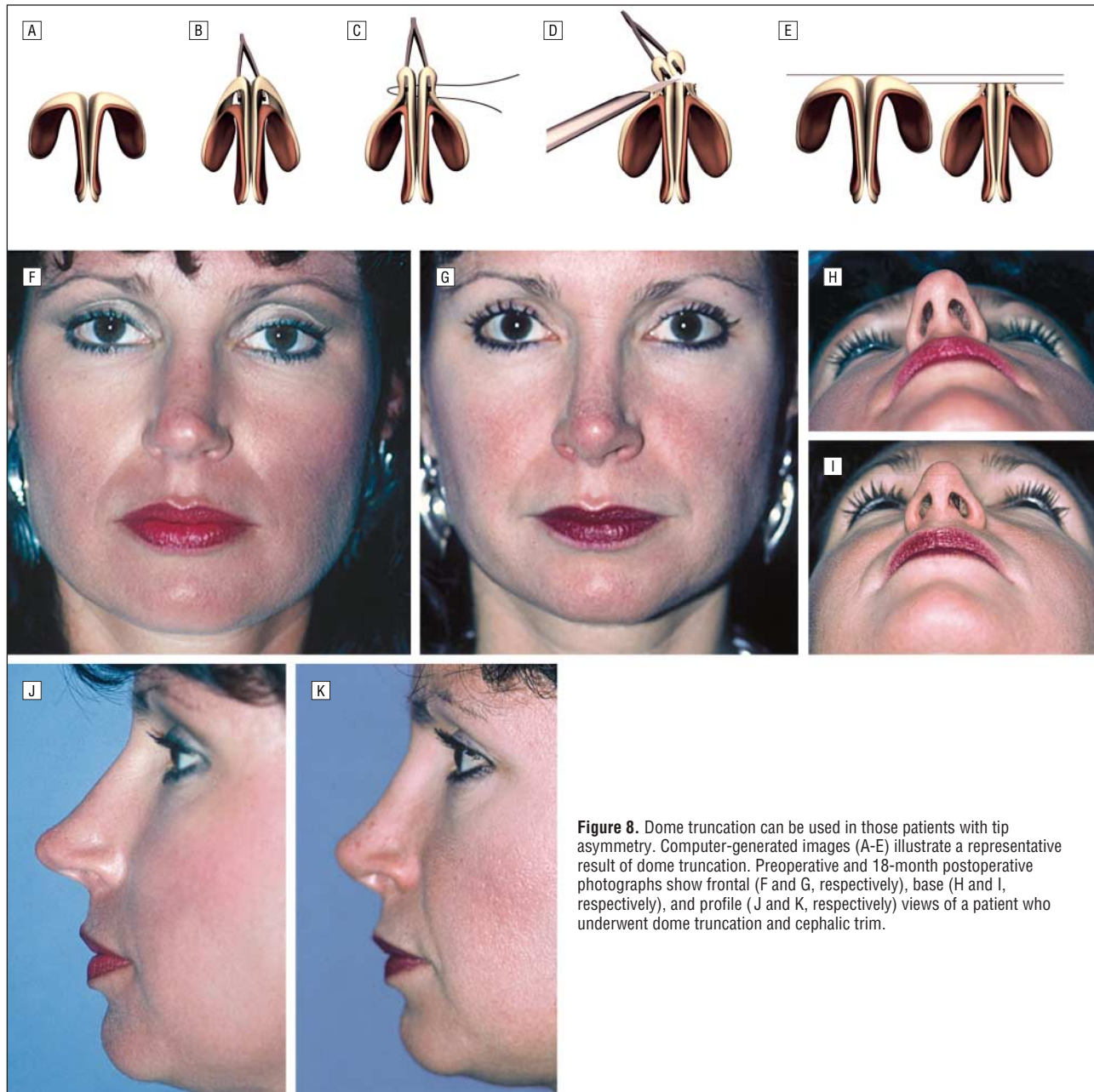

Figure 8. Dome truncation can be used in those patients with tip asymmetry. Computer-generated images (A-E) illustrate a representative result of dome truncation. Preoperative and 18-month postoperative photographs show frontal (F and G, respectively), base (H and I, respectively), and profile (J and K, respectively) views of a patient who underwent dome truncation and cephalic trim.

incision is made at the junction of the septal cartilage and membranous septum and causes tip retrodisplacement by releasing the attachments from the medial crural footplates to the caudal septum. The nasal incisions are then carefully closed. The alar base should then be carefully evaluated to ensure that alar flaring has not occurred owing to the retrodisplacement. Occasionally, alar wedge excisions may be required to decrease the excess alar length and flare. The nose is then taped to provide nasal tip support, and a splint is placed over the dorsum. The splint is removed after 1 week, and the nose is retaped for approximately 5 days to help support the tip during the early postoperative period.

RESULTS

From 1991 to 2002, 130 cases used 1 or more of the senior author's preferred methods to treat overprojection.

Ten patients were excluded because of the reconstructive nature of their surgery. On average, these excluded patients had undergone 3 previous rhinoplasty procedures before our attempts at correction. Of the remaining 120 patients, 3 (2.5%) required minor revision of dorsal irregularities, and another 5 (4.2%) required tip revision. The remaining 112 patients (93.3%) were satisfied without qualification. Only 9 patients (7.5%) underwent alar base reduction. Another 8 patients (6.7%) underwent chin implants. Also of interest, only 3 patients (2.5%) in this cohort underwent radix grafts. Sixteen (13.3%) of the patients had had previous rhinoplasty performed by outside physicians. Twenty-two patients (18.3%) were classified as having tension nose. Only 1 patient had postoperative epistaxis, and there were no cases of postoperative functional complaints.

Full-transfixion incisions were made in 30 patients (25.0%). Forty-seven patients (39.2%) underwent LCO, 11 patients (9.2%) underwent MCO, 9 patients (7.5%) underwent a combination of LCO and MCO, and another 15 patients (12.5%) underwent dome truncation.

COMMENT

The overall surgical principles involved in the treatment of the overprojected nose were clearly elucidated by Tardy et al⁸ and many others. The surgeon can (1) reduce excessive tip support mechanisms, (2) reduce overdeveloped anatomic components, and (3) normalize adjacent anatomic components. In the 1930s, Joseph⁹ and Safian¹⁰ first described deprojection of the nasal tip by shortening the medial and lateral crura. Since then, refinement of the procedure via more conservative measures, which included maintaining vestibular skin, suturing divided components, and overlapping these components, have variously been developed for the lateral crura.^{5,11,12} Meanwhile, Lipsett¹³ pioneered shortening of the medial crura in 1959. Similar modifications as with the lateral crura have subsequently been described by Berman,¹⁴ McCurdy,¹⁵ and Parkes et al.¹⁶ Now we would like to incorporate our 12-year experience with a technique that we have defined as MCO.

The elegance of both LCO and MCO lies in the fact that no bridges are burned. Because no cartilage is excised, the surgeon is left with the flexibility to modify the result on the operating table. If too much deprojection is seen, the overlapping sutures can be released and reapproximated with less overlay. Furthermore, some have argued that excision of portions of the medial crura results in a high risk of tip contour irregularities—notching/bossae—as a result of displacement and distortion of the transected, weakened cartilage¹⁷; Webster and Smith¹⁸ encountered this difficulty with their lateral crural flap technique. With LCO and MCO, time has shown that because no cartilage is excised, and because sutures are used to control and maintain the correction, the overlapped crura maintain their integrity for years without buckling or any of the other associated complications. Moreover, with overlapping of cut cartilage segments, more strength is imparted to the correction. On the other hand, when cartilage segments are excised and sewn end to end as other authors advocate, the edges migrate with time and afford little stability. Our experience has shown that with MCO and the overlap suturing of the cut ends, tip support can be maintained or obtained without the need for a columellar strut. Because the edges are overlapped, we are not relying on a simple fibrous union, and there is much less likelihood of development of notching or collapse. In fact, the only case of MCO that needed revision in our experience was secondary to partial resorption of irradiated cartilage and not due to any tip irregularity arising from MCO.

Numerous authors have pointed to the tripod theory and suggested that when the medial crura are shortened

in relation to the lateral crura, there would be a high tendency for alar flaring. That has not been our finding when MCO is used. In fact, no cases when MCO was used alone necessitated alar base reduction. Even more surprising was our finding that in our entire experience with deprojection, only 7.5% of the patients needed alar base reduction, and many of these patients desired this reduction before deprojection.

CONCLUSIONS

We found that this algorithm for deprojection accomplishes the needed deprojection in every situation we have encountered. Most importantly, our long-term experience with these procedures has shown that, when properly used, the algorithm can be used to accomplish retrodisplacement of the tip with the desired changes required in tip rotation in a safe, functionally appropriate way. As with any rhinoplasty, tip asymmetries can arise. However, our revision rate of 4.2% for tip irregularity and our finding that no patients had postoperative functional complaints allows us to feel confident that this algorithmic paradigm can be used to accomplish tip deprojection in almost any circumstance.

Accepted for Publication: July 28, 2005.

Correspondence: Russell W. H. Kridel, MD, Facial Plastic Surgery Associates, 6655 Travis St, Suite 900, Houston, TX 77030 (rkridel@todaysface.com).

REFERENCES

1. Crumley RL, Lanser M. Quantitative analysis of nasal tip projection. *Laryngoscope*. 1988;98:202-208.
2. Byrd HS, Hobar PC. Rhinoplasty: a practical guide for surgical planning. *Plast Reconstr Surg*. 1993;91:642-654.
3. McKinney P, Sweiss I. A clinical definition of an ideal nasal radix. *Plast Reconstr Surg*. 2002;109:1416-1418.
4. Kridel RWH, Konior RJ. Controlled nasal tip rotation via the lateral crural overlay technique. *Arch Otolaryngol Head Neck Surg*. 1991;117:411-415.
5. Kridel RWH, Konior RJ. Dome truncation for management of the overprojected nasal tip. *Ann Plast Surg*. 1990;24:385-396.
6. Konior RJ, Kridel RWH. Controlled nasal tip positioning via the open rhinoplasty approach. *Facial Plast Surg Clin North Am*. 1993;1:53-62.
7. Sheen JH, Sheen AP. *Aesthetic Rhinoplasty*. 2nd ed. St Louis, Mo: Mosby-Year Book Inc; 1987:70-74.
8. Tardy ME, Walter MA, Patt BS. The overprojecting nose: anatomic component, analysis and repair. *Facial Plast Surg*. 1993;9:306-317.
9. Joseph J. *Nasoplastik und Sonstige Geichts Plastik Nebst Mammoplastik*. Leipzig, Germany: Curt Kabitzsch; 1931.
10. Safian J. *Corrective Rhinoplastic Surgery*. New York, NY: P Hoebar; 1935.
11. Smith TW. Reliable methods of tip reduction. *Arch Otolaryngol*. 1978;104:564-569.
12. Brennan HG. Dome-splitting technique in rhinoplasty with overlay of lateral crura. *Arch Otolaryngol*. 1983;109:586-592.
13. Lipsett EM. A new approach to surgery of the lower cartilaginous vault. *Arch Otolaryngol*. 1959;70:42-47.
14. Berman WE. Surgery of the nasal tip. *Otolaryngol Clin North Am*. 1975;8:563-574.
15. McCurdy JA. Reduction of excessive nasal tip projection with a modified Lipsett technique. *Ann Plast Surg*. 1978;1:478-480.
16. Parkes MH, Kanodia R, Kern EB. The universal tip: a systematic approach to aesthetic problems of the lower lateral cartilages. *Plast Reconstr Surg*. 1988;81:878-890.
17. Foda HMT. Alar setback technique: a controlled method of nasal tip deprojection. *Arch Otolaryngol Head Neck Surg*. 2001;127:1341-1346.
18. Webster RC, Smith RC. Lateral crural retrodisplacement for superior rotation of the tip in rhinoplasty. *Aesthetic Plast Surg*. 1979;3:65-78.